



Research Article

www.ijrap.net



AYURVEDIC MANAGEMENT OF ACUTE ANTERIOR UVEITIS (PITTAJA ADHIMANTHA): A CASE STUDY

Pushpa Raj Poudel ^{*1}, Ashwini MJ ²

¹PG Scholar, Sri Dharmasthala Manjunatheshwara College of Ayurveda and Hospital, Hassan, India

²Professor and Head of the Department, Department of Shalakyana Tantra, Sri Dharmasthala Manjunatheshwara College of Ayurveda and Hospital, Hassan, India

Received on: 15/01/18 Accepted on: 15/02/18

*Corresponding author

E-mail: pundanraj@gmail.com

DOI: 10.7897/2277-4343.09244

ABSTRACT

Uveitis is a broad term used to describe the inflammatory pathology of vascular layer of eyeball. It is composed of a diverse group of disease entities, which in total has been estimated to cause approximately 10% of blindness. Based on the anatomical involvement of eye, uveitis is broadly classified into anterior, intermediate, posterior and Panuveitis. Anterior uveitis denotes intraocular inflammation that involves the iris (iritis), anterior part of the Ciliary body (anterior cyclitis), or both (iridocyclitis). The signs and symptoms presented in anterior uveitis can be compared with Pittaja Adhimantha (Anterior uveitis) in Ayurveda. SUN (Standard Uveitis Nomenclature) working group has described the disease acute, chronic and recurrent on the basis of its course. Anterior uveitis is the commonest form with comparably less sight threatening uveitis. It can lead to serious complications such as cataract, glaucoma, and cystoids macular edema if not diagnosed and treated promptly. A 21-year-old male patient residing in Hassan came to Sri Dharmasthala Manjunatheshwara college of Ayurveda and Hospital, Hassan complaining of redness, pain, watering and photophobia in Right eye for one day. The case was assessed and diagnosed with SUN working group criteria. The case was managed effectively with amapachana (Morbid factor digestion), Virechana (purgation), Pancha lauha shalaka agnikarma (Ayurvedic cautery) over eyebrows, Seka (Medicated washing of eye), avagundana (Mild medicated hot fomentation), oral intake of triphala guggulu and Bhoonimbadi kwath. Patient got significant relieve from sign and symptom on the day 3rd of treatment and cured by 7th day of treatment. The management of anterior uveitis opt the use of steroids, antibiotics, cycloplegic and NSAIDs for long term in modern medicine. The above-mentioned disease can be managed with Amapachana (digestion of morbid factors of the body), virechana (Medicated purgation), Shothahara (anti-inflammatory), Vedanashamaka (Analgesic), Sravahara, sthanika chikitsa (Local measures) and Pittahara chikitsa (Pitta morbid factor pacifying treatment) of Ayurveda. 50 % of acute anterior uveitis is idiopathic in nature, so the condition can be managed effectively adopting Ayurveda Netra Roga chikitsa. An acute anterior uveitis is very painful and photophobia condition which is managed effectively by Ayurveda. Ayurveda can be ray of hope in the management of uveitis which is very pathetic to conventional system of medicine.

Keywords: Uveitis, Adhimantha, Glaucoma, Cystoid macular edema

INTRODUCTION

Anterior Acute uveitis is presumed to be RED eye in which CELLS and FLARE are present in anterior chamber¹

Table 1: Sun Working Group Description of Uveitis³

Onset	Sudden or insidious
Duration	Limited (3 months or less) or persistent
Clinical course	Acute (sudden onset and limited duration) Recurrent (Repeated episodes separated by untreated inactive periods) Chronic (persistent duration, with relapse less than 3 months after discontinuation of treatment. Remission (No visible cells for 3 months or longer)

Acute anterior uveitis typically presents with a painful, photophobic, watering, red eye and blurred vision².

Acute anterior uveitis may mimic the sign and symptoms of conjunctivitis, but one can easily differentiate by its cardinal signs.

Anterior uveitis can present with an acute, chronic, or recurrent form, the severity of symptoms range from no symptoms in chronic disease to very severe symptoms in acute uveitis. The

complications of anterior uveitis include cataract, glaucoma and cystoids macular edema.

The prognosis is usually good in most idiopathic and HLA- B 27 related acute anterior if adequate prompt measure has been followed⁴.

The above presented disease can be compared with Adhimantha in Ayurveda.

Adhimantha is a Sarvagata Eye disease in which patient complains pain in eye along with hemicranias as if churning type⁵.

Based on dosha dominance (morbid factor), the disease entity can be further categorized into Vataja, Pittaja, Kaphaja and Raktaja. Presently aforementioned condition can be correlated with pittaja adhimantha.

Pittaja adhimantha⁶ defined as a congestion of blood vessels in the eye, sravi (discharges), patient feel as if burnt by fire, burning sensation as if from caustic, eye looks like piece of liver (discolored to brownish red), inflamed eyelid margin, perspiration, yellowish appearance of all objects, unconsciousness, burning sensation in head. It is curable disease.

MATERIALS AND METHODS

Present study was carried out in accordance with ethical principle by following international conference on Harmonization- Good clinical practices (ICH-GCP). Informed consent was taken prior to case study.

The study is carried out in accordance with SUN working group methodology and Algorithmic approach in diagnosis and management of uveitis⁷.

Case Report

A 21year male patient residing in Hassan came to Sri Dharmasthala Manjunatheswara college of Ayurveda and Hospital, Hassan complaining of redness, pain, watering and photophobia in Right eye for one day. This unilateral redness of eye is happening since 3 years once in year which is lasting not more than 2 weeks and he is taking treatment since then in SDM Hospital, Hassan.

There was no underlying systemic and infectious illness in the past and present. He is admitted here for the treatment of his redness of eye.

On examination

(A) General examination

- General condition: Anxious
- Anemia: absent
- Lymphadenopathy: absent
- Clubbing: Absent
- Cyanosis: absent
- Dehydration: absent
- Pulse: 78 beats per minute
- B.P: 130/80 mm Hg
- Temperature: 98.6 °F
- Weight: 68 kg

(B) Systemic examination

- Respiratory system: Bilateral equal air entry with normal vesicular sound heard.
- Skin: Normal pigment with texture. Not any abnormality detected.
- Cardiovascular: S1S2M0
- Central Nervous system: Oriented with time place and person, good judgment and insight.
- Musculoskeletal system:
 - a. Gait: Normal straight and erect
 - b. Arm: Not any abnormality detected
 - c. Leg: Not any abnormality detected.
 - d. Spine: Normal primary and secondary curve. Not any abnormality detected.

(C) Ocular examination

Head Posture: Straight and erect.

Facial symmetry: Bilateral symmetrical of eyebrows.

- Symmetrical Naso-labial fold.
- Symmetrical angle of mouth.

Ocular posture: RE was semi closed due to photophobia. Otherwise B/L visual axis was parallel to each other in primary position of gaze.

Table 2: Visual Acuity

Snellen's visual acuity	RE	LE	BE
Before treatment	6/18 (p)	6/6 (p)	6/6 (p)
After treatment	6/9	6/6	6/6

RE: Semi closed due to photophobic.

LE: Normal. Upper eyelid touches the 1/6th part of upper cornea. Lower eye lid just touches the inferior limbus.

Eye lashes

RE- wet eyelashes. Direction of cilia: Normal.

LE - Normal in color, contour and direction. No Trichiasis, Poliosis and distichiasis in both eyes.

Lacrimal apparatus

Normal.

No Regurgitation.

Skin over Lacrimal Sac: no swelling, redness and discharge.

No Dacrycystitis and stenosis of punctum.

Conjunctiva

RE: circumciliary congestion+++,

LE: No congestion, chemosis, discoloration, Pterygium, papilla, follicules, cyst and pinguecula.

Sclera: severe circumciliary congestion RE.

Cornea

Size: No micro cornea and megalocornea in B/L cornea.

Shape: watch dial shaped (Cancavo- convex) in B/L cornea.

Ectasia: No keratoconus, keratoglobus, cornea plana and anterior staphyloma in B/L cornea.

Transparency: altered due to corneal band keratopathy in RE and transparent in LE.

Surface: smooth in BE

Sensations: Hypersensitive in RE, intact and normal in LE.

Anterior Chamber

Slit lamp examination findings of anterior chamber of RE are summarized in

Table 3: SUN (Standardization Of Uveitis Nomenclature): 1mm X 1mm slit beam view

Cells		Flare	
Grade	Cells in field	Grade	Description
2+	16-25	2+	Iris and lens details clear

Iris pigment detached and floating in anterior chamber.

LE: Anterior chamber normal. No cells, no flare.

Iris

Normal crypts, ridges and collarets are partly altered in RE.

Iris pigment detached partly.

LE -Normal iris.

Pupil

Site: slightly nasal eccentric

Number: single

Shape: round
 Reflexes: Regular present
 Mydriasis and miosis: Absent

Lens

Elephant blue hue is present.
 Part of iris pigment attached in lens
 IOP: RE- 14 mmHg, LE- 16 mm Hg

Fundus evaluation

RE: Media is Hazy. fundus partly seen.
 FLR (Foveal Light Reflex) – present.
 Optic disc: normal, NRR (Neuro Retinal Rim) follows ISNT rule.
 Cup disc ratio - 0.4
 Blood vessels – normal
 LE: media clear. fundus clearly visualized.
 FLR – present, optic disc – normal, NRR follows ISNT rule.
 Cup disc ratio- 0.3
 Blood vessels - normal

TREATMENT

The patient was admitted in the SDMCAH, Hassan for 7 days.
 The following line of treatment was executed⁸.

Amapachana

- a) Tab Chitrakadi vati 2 tab three times per day for first day.
- b) Panchakola phanta 100ml three times per day for first day.

Sadhyovirechana: Purgation done by Gandharvahastadi eranda tail 60 ml with 100 ml jeera jala

Agnikarma⁹: By Panchalauha shalaka in Bhruvopari and Bhru Puchhanta (above to eyebrows and temporal side of eye brows)

Kriyakalpa measures

- a) Seka with Triphala, Yashthi kashya
- b) Avagundana with Dhanyka and Haridra in Triphala Kashya

Oral Medication

- a) Triphala Guggulu¹⁰ one tab twice a daily for 7 days.
- b) Sudarshana Ghana vati¹¹ one tab twice a daily for 7 days
- c) Syr. Bhoonimbadi kwath¹² three teaspoonful twice a daily for 7 days.

RESULT

Significant changes in signs and symptoms were noticed in before treatment and after treatment with short course of 7 days. On first day patient was complaining of redness, photophobia, pain, watering and blurredness of vision. On his third day of treatment patient classical signs and symptoms were reduced by 50%. In comparison to his first day, patient was totally asymptomatic on the 7th day (last day) of treatment.

DISCUSSION

Anterior Uveitis is an intraocular inflammation of the uveal structures anterior to the middle of the vitreous cavity. This disease is associated with ocular trauma as well as many systemic diseases, including idiopathic, infectious (Herpes, syphilis, tuberculosis and lyme), Noninfectious (juvenile rheumatoid arthritis, ankylosing spondylitis, Reiter's syndrome, sarcoidosis, Multiple sclerosis, HLA B- 27 positivity), Masquerade (Neoplasit and Non-neoplastic)¹³. Idiopathic is commonest one and accounts for 50% of its occurrence. There are certain conditions which are commonly termed as red eye are mentioned below.

Table 4: Differential Diagnosis of Red Eye- Typical presenting symptoms¹⁴

Disease	Pain	Reduced vision	Photophobia	Halo	Discharge	Other
Acute Anterior uveitis	Mild to moderate	Reduced or normal	Present	Rarely	Tearing or absent	
Acute glaucoma	Severe	Severely reduced	Present/ absent	Present	Tearing or absent	Vomiting
Scleritis	Severe	Reduced or normal	Absent	Absent	Absent	
Episcleritis	Mild or absent	Normal	Absent	Absent	Absent	Gritty
Corneal ulcer bacterial	Moderate	Reduced or normal	Present	Absent	Purulent	
Herpes simplex keratitis	Moderate	Reduced or normal	Present	Absent	Watery	
Corneal erosion	Moderate	Reduced or normal	Present	Absent	Tearing	
Bacterial conjunctivitis	Absent	Normal	Absent	Absent	Purulent	Gritty
Viral conjunctivitis	Absent	Normal	Absent	Absent	Watery	Gritty
Allergic conjunctivitis	Absent	Normal	Absent	Absent	Mucoid or absent	Itch

Considering the signs and symptoms of pittaja adhimanth such as redness of eye, congestion, severe pain and burning as if from caustic and headache can be seen in acute anterior uveitis.

Pittaja adhimatha is vyadhana sadhya vyadhi¹⁵.

The diagnosis of acute anterior uveitis includes the brief relevant medical history and skill full slit lamp examination of ocular structures.

Systematic assessment can be made with following SUN guidelines¹⁶ for CELLS and FLARE in anterior chamber.

The primary objective of management of Acute anterior uveitis are providing relief of pain and photophobia, elimination of inflammation, prevention of structural complication such as synechiae, secondary cataract and glaucoma and preservation and restoration of good visual function.

The management of acute anterior uveitis includes the use of steroids, mydriatic/ cycloplegics, NSAIDs and immunosuppressive agent in selective cases¹⁷.

In Ayurveda pittaja adhimantha can be managed with Sira vyadhana or aushadha.

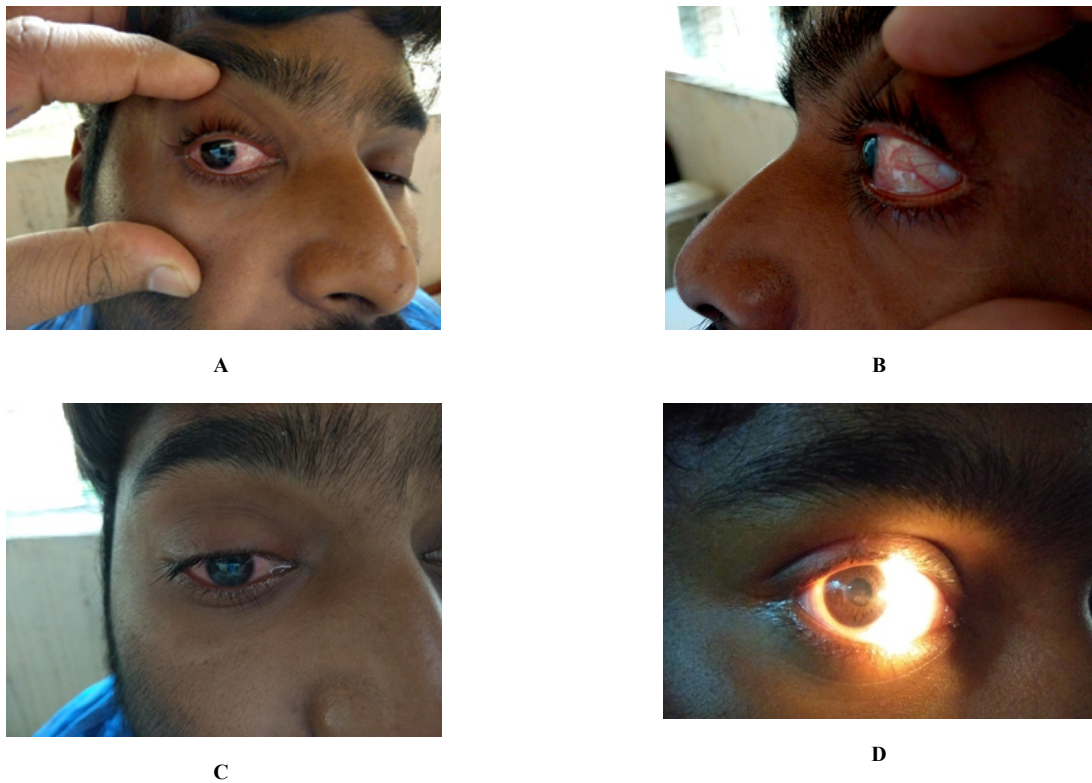


Figure 1: A & C: BT- Photophobia, Red eye, Lacrimation; B: Circumciliary congestion Slit view: D: Flare, Cells and iris pigment in AC




Figure 2: A- AT Diffuse light examination: Marked reduction of signs and Symptoms of Acute Anterior uveitis
B- AT Slit examination: Healed Anterior uveitis with retaining iris pigment in A.C

Vyadhan (sneha purvaka siramokshya) is indicated after series of Apatarpana and amapachana.

The Aushadha sadhya protocol follows the virechana, pitta visarpavidhana chikitsa such as application of medicated thin paste made up of (Sheeta veerya) usheera and chandhan, Seka, Alepa, nasya and anjana¹⁸.

Severe pain in the adhimantha can be managed with Agni karma (Para surgical procedures) mentioned in Ayurveda.

Amapachana, Shothahara, vedanashsamaka and Sravahara can be achieved with triphala guggulu, Sudarshana Ghana vati and Bhoonimbadi kadha.

These above mentioned drugs has antioxidant, antimicrobial, anti-inflammatory, immunomodulative, bitter tonic as well as excellent wound healing properties.

The complete samprapti vighatana can be done with rational use of Ahara vihara and Aushadha and condition can be managed effectively.

Sthanika chikitsa (Local measures) adopted include Seka with triphala, lodhra and yashthimadhu kashaya and sthanika avagundana with Dhanyaka and haridra with triphala kashaya which help in mark reduction of signs and symptoms of ocular discomforts.

CONCLUSION

On the basis of etiology, sign and symptom, Pittaja Adhimatha can be correlated with clinical presentation of anterior uveitis. Anterior Uveitis is sight threatening condition which may end up with inevitable blindness, so it should be diagnosed and treated in early hour. Anterior Uveitis can be diagnosed thorough ocular examination and brief relevant medical history.

Anterior uveitis is sometimes multidisciplinary disease (Rheumatology, Gastroenterology, Venerology, Dermatology and Tropical medicine) entity so the expertise from the different discipline of medicine has to be consulted and counseling should be made. In case of systemic involvement of uveitis, it needs ancillary investigation in tailored approach. Patient sight is prime concern, so no hesitation should be sought in proper diagnosis and treatment. If anterior uveitis diagnose and treated in ample hour the sequel of its complication can be avoided.

By undertaking Ayurveda principle of Netra chikitsa and proper understanding of nidana, samprapti, rupa and Lakshana the above mentioned disease entity can be managed safely. Samprapti vihgatana chikitsa can be done with optimizing amapachana, pittahara, Shothashamaka, vedanashamaka as well as local measures of treatment (seka, avagundana). As idiopathic is most common form of anterior uveitis so can be managed safely by Ayurveda with due care.

REFERENCES

1. Stephen D. Anesi, C. Stephen fosters. Advanced ocular care. A cover story. Jan/Feb 2011,p.32-34 [Downloaded free from http://eyetubeod.com/advancedocularcare/pdfs/aoc0111_f_foster.pdf and cited on 21st August 2017]
2. Jack j kanski. uveitis. Brad Bowling Kanski's clinical ophthalmology.Eighth edition.Elsevier. 2016. p. 397
3. Jabs DA, Nussenblatt RB, Rosenbaum JT Standardization of Uveitis Nomenclature (SUN) working group. Standardization of uveitis nomenclature for reporting clinical data. Results of the First international workshop. Am J Ophthalmol. 2005; 140:509-16. [Cited on August 23,2017].
4. Jack j kanski. uveitis. Brad Bowling Kanski's clinical ophthalmology. Eighth edition. Elsevier. 2016. p.396
5. Maharshi Sushruta. Sushruta with Nibandha Sangrha commentary by Shri Acharya Dalhana and Nyaya chandrika Panjika of shri Acharya Gayadas. Edited by Acharya yadavji Trikamji.Uttataratantra Ch.6, Ver. 10-1. Reprint Ed. Varanasi: Chaukhamba Oreintalia; 2014. p. 604.
6. Maharshi Sushruta. Sushruta with Nibandha Sangrha commentary by Shri Acharya Dalhana and Nyaya chandrika Panjika of shri Acharya Gayadas. Edited by Acharya yadavji Trikamji.Uttataratantra Ch.7, Ver. 14-5. Reprint Ed. Varanasi: Chaukhamba Oreintalia; 2014. p. 604.
7. SR Rathinam, Manohar Babu. Algorithmic approach in the diagnosis and management of Uveitis. Indian Journal of Ophthalmology. [Downloaded free from <http://www.ijo.in> on Wednesday, November 22, 2017, IP: 157.49.9.224]
8. Maharshi Sushruta. Sushruta with Nibandha Sangrha commentary by Shri Acharya Dalhana and Nyaya chandrika Panjika of shri Acharya Gayadas. Edited by Acharya yadavji Trikamji .Uttataratantra Ch.10, Ver. 1-6. Reprint Ed. Varanasi: Chaukhamba Oreintalia; 2014. p. 612-613.
9. Pandit Sharangadhar Acharya. Sharangadhara with Bhisakvar Adhamalla's Dipika and Pandit Kasirama's Gudhartha –Dipika commentary. Uttarakhanda. Ch.13, Ver.23-4. Reprint Ed. Varanasi: Chaukhamba Orientalia; 2016. p. 382.
10. Shri Govinda Das. Bhaisajyaratnawali with Vidhyotani commentary. Edited by Brahma Shankar mishra, Ambika Dutta shastri and Rajeshwara datta Shastri. Vrana Shotha chikitsa prakaran.Ch.47, Ver.51. 19th Edition. Varanasi. Chaukhamba Orientalia; 2008. p. 849.
11. Shri Govinda Das. Bhaisajyaratnawali with Vidhyotani commentary. Edited by Brahma Shankar mishra, Ambika Dutta shastri and Rajeshwara datta Shastri. Jwarachikitsa prakaran.Ch.5, Ver.445-454. 19th Edition. Varanasi. Chaukhamba Orientalia; 2008. p. 117
12. Shri Govinda Das. Bhaisajyaratnawali with Vidhyotani commentary. Edited by Brahma Shankar mishra, Ambika Dutta shastri and Rajeshwara datta Shastri. Jwarachikitsa prakaran.Ch.5, Ver.445-454. 19th Edition. Varanasi. Chaukhamba Orientalia; 2008. p. 77.
13. Jack j kanski. uveitis. Brad Bowling Kanski's clinical ophthalmology.Eighth edition.Elsevier. 2016. p. 397
14. Catherine M Guly, John Forrester. Investigation and management of uveitis. British medical journal.Ocotber 16, 2010, Vol. 341. doi: 10.1136/bmj.c4976 [downloaded free from www.bmj.com] [cited on 20th august 2017]
15. Maharshi Sushruta. Sushruta with Nibandha Sangrha commentary by Shri Acharya Dalhana and Nyaya chandrika Panjika of shri Acharya Gayadas. Edited by Acharya yadavji Trikamji.Uttataratantra Ch.8, Ver.8-9. Reprint Ed. Varanasi: Chaukhamba Oreintalia; 2014. p.610.
16. Jabs DA, Nussenblatt RB, Rosenbaum JT Standardization of Uveitis Nomenclature (SUN) working group. Standardization of uveitis nomenclature for reporting clinical data. Results of the First international workshop. Am J Ophthalmol. 2005; 140:509-16. [Cited on August 23, 2017].
17. Jack j kanski. uveitis. Brad Bowling Kanski's clinical ophthalmology.Eighth edition.Elsevier. 2016. p.397
18. Maharshi Sushruta. Sushruta with Nibandha Sangrha commentary by Shri Acharya Dalhana and Nyaya chandrika Panjika of shri Acharya Gayadas. Edited by Acharya yadavji Trikamji .Chikitsasthana Ch.17, Ver. 6-13. Reprint Ed. Varanasi: Chaukhamba Oreintalia; 2014. p. 466.

Cite this article as:

Pushpa Raj Poudel & Ashwini M J. Ayurvedic management of acute anterior uveitis (pittaja adhimantha): A case study. Int. J. Res. Ayurveda Pharm. 2018;9(2):113-117 <http://dx.doi.org/10.7897/2277-4343.09244>

Source of support: Nil, Conflict of interest: None Declared

Disclaimer: IJRAP is solely owned by Moksha Publishing House - A non-profit publishing house, dedicated to publish quality research, while every effort has been taken to verify the accuracy of the content published in our Journal. IJRAP cannot accept any responsibility or liability for the site content and articles published. The views expressed in articles by our contributing authors are not necessarily those of IJRAP editor or editorial board members.