



Research Article

www.ijrap.net



EFFECTIVENESS OF PAPAYA PULP DRESSING ON DIABETIC FOOT ULCER

S.Indumathy¹, P.Thenmozhi^{2*}, P.Mangala Gowri³

¹M.Sc(N) Student, Saveetha College of Nursing, SIMATS, Chennai, India

²Associate Professor, Saveetha College of Nursing, SIMATS, Chennai, India

³Principal, Saveetha College of Nursing, SIMATS, Chennai, India

Received on: 10/07/18 Accepted on: 19/08/18

*Corresponding author

E-mail: thenmozhi.sethu@gmail.com

DOI: 10.7897/2277-4343.095160

ABSTRACT

Background of the study: Foot complications are common in diabetic patients and are considered one of the most expensive diabetes complications to treat. Different strategies are available to treat diabetic foot ulcer. One amongst is papaya pulp dressing which is a non-pharmacological method of treatment. Aim: To determine the effectiveness of papaya pulp dressing on wound healing among patients with diabetic foot ulcer. Methods: Quasi experimental pre-test and post-test design research design was adopted to conduct the study with 60 samples who met the inclusion criteria in Saveetha Medical College and Hospital. Samples were allocated into experimental group (n=30) and control group (n=30) by convenience sampling technique. The demographic questionnaire was completed at the beginning of the study. Pre-test was conducted by using Bates-Jensen Wound Assessment Tool in both experimental and control group. Papaya pulp dressing was administered after clean the wound aseptically from same day onwards among experimental group and the control group was continued with the routine treatment. Post-test was conducted after 2 weeks with same tool for both the group. Data were analyzed using SPSS. Results: A significant improvement in the level of wound healing was observed at the level of $p < 0.001$ in the experimental group and also found significant difference between the experimental and control group. Conclusion: It is concluded that papaya pulp dressing has proved the beneficial effect in healing of diabetic foot ulcers owing to the quick curative action, cost effectiveness and easy availability.

Keywords: Diabetic foot ulcer, papaya pulp, wound healing, diabetes mellitus, diabetic complications

INTRODUCTION

Diabetes mellitus is one of the important public health issue and challenging the world in the 21st century. It is severe and debilitating chronic disease that develops in nearly 5% of the world's population. If left untreated, diabetes can cause many complications such as acute diabetic ketoacidosis, non-ketotic hyperosmolar, diabetic foot ulcer and coma or death. Diabetic foot is one of the most significant and devastating complications of diabetes. It is defined as a foot affected by ulceration that is associated with neuropathy and/or peripheral arterial disease of the lower limb in a patient with diabetes. The prevalence of diabetic foot ulcer in the diabetic population is 4–10%. The condition is more frequent in older patients. It is estimated that about 5% of all patients with diabetes present with a history of foot ulceration. The lifetime risk of diabetic patients developing this complication is 15%.¹

The majority (60–80%) of foot ulcers will heal, while 10–15% of them will remain active, and 5–24% of them will finally lead to limb amputation within a period of 6–18 months after the first evaluation. Neuropathic wounds are more likely to heal over a period of 20 weeks, while neuro-ischemic ulcers take longer and will more often lead to limb amputation.² It has been found that 40–70% of all non-traumatic amputations of the lower limbs occur in patients with diabetes. Furthermore, many studies have reported that foot ulcers precede approximately 85% of all amputations performed in diabetic patients.³ Studies show severity of diabetic foot ulcer is the strongest significant risk factor of amputation of diabetic patients. In developed countries 1 in every 6 people with diabetes will have ulcer during life time. The risk is even higher in developing countries.⁴

Risk factors associated with diabetic foot ulcer include peripheral neuropathy, peripheral vascular disease, weak immune system and foot trauma were also reported risk factors in the

pathophysiology of foot ulcer. People with diabetes often develop diabetic neuropathy due to several metabolic and neurovascular factors. Some studies have shown that foot ulceration is more common in men with diabetes than in women.⁵ Social factors, such as low socioeconomic status, poor access to healthcare services and poor education are also proven to be related to more frequent foot ulceration.⁶ India has the highest number of people with diabetes in the world. Diabetic foot care is one of the most ignored aspects of diabetes care in India. Due to social, religious, and economic compulsions, many people walk barefoot. Poverty and illiteracy lead to usage of inappropriate foot wear and late presentation of foot lesions.⁷ Studies have reported that health related problems and socio economic crisis and quality of life is adversely affected by diabetic foot ulcer. Risk factors for diabetic foot complications are highly prevalent, at a higher rate in morbidity and mortality in addition to economic impact of the complications.⁸ It will continue to be a heavy economic burden if preventive measures are not taken.⁹ The length of hospital stay was longer by the severity of inflammation.¹⁰

The management of diabetic foot ulcers remains a major therapeutic challenge which implies an urgent need to review strategies and treatments in order to achieve the goals and reduce the burden of care in an efficient and cost-effective way. Different strategies including honey dressings, medicated dressings, povidone iodine dressings, platelet rich plasma dressings, saline dressings, vacuum dressings and papaya dressings are available in the management of diabetic foot. *Carica Papaya* (pawpaw) has been used widely as a wound healing agent, particularly in many resource-poor countries where its ready accessibility is attractive. It is an important and promising natural medicinal plant which could be utilized in several pharmaceutical and medical applications because of its cost effectiveness, availability and safety. Papaya dressing is important and promising strategy in caring diabetic foot ulcer which facilitates wound healing proven by several studies. Many research studies have shown the

effectiveness of papaya dressing among diabetic foot ulcer patient. *Carica papaya* is one of the most effective sources of natural medicine, easily available, cost effective and widely used in pharmacological applications.¹¹ Hence the investigators had made the observation with the hypothesis of improvement in the level of wound healing after administration papaya pulp dressing in experimental group than control group.

MATERIALS AND METHODS

Quasi experimental equivalent control group design was adopted to conduct the study among patients with diabetic foot ulcer. It was conducted at Saveetha Medical College Hospital Chennai, after obtaining formal permission from the hospital authority. The investigators explained about the study and obtained the informed consent from the participants. Ethical approval was obtained from Institutional Human Ethics Committee of Saveetha Medical College and Hospital (007/06/ 2017/IEC/SU; Dated 10th October 2017) and Institutional Scientific Review Board of Saveetha College of Nursing 007/ISRB/SCON; dated 7th July 2017). The samples who included in the study were patients with age group between 45 to 65 years of both the sex, meeting the Wagner's ulcer grade II and III and were willing to participate in the study. Sixty patients with diabetic foot ulcer were selected for the study by using a convenience sampling technique. Experimental group (n=30) were selected from I unit of male & female surgical wards and 30 samples for control group were selected from II unit of male & female surgical wards. Demographic variables and clinical variables were collected by using structured questionnaire. The pre-test assessment was done by using Bates-Jensen wound assessment tool. The experimental group was received papaya pulp dressing. Papaya pulp was taken from fresh ripened papaya after removing the skin and seeds. It was prepared freshly every day and applied on the wound after cleaned the wound aseptically. Wound covered with sterile gauze piece. Dressing was changed every 24 hours for 14 days and the control group were continued the routine care of the hospital. The posttest assessment was done at the end of fourteenth day by using Bates-Jensen wound assessment tool for both experimental and control groups. Data were analyzed using SPSS statistical package.

RESULTS

The present study observed that that majority 11(36.67%) of the patients were in the age group of 56 – 60 years and 18(60%) were male and 18(60%) of them had not followed any foot care practices. Clinical variables showed that 100% of them had had type II diabetes with the duration of 2-4 years and above and 22(73.33%) received both insulin and oral hypoglycemic agent. The present study also found that in pre-test, 24(80%) of them had wound regeneration and six (20%) of them had wound degeneration in experimental group, all of them 30(100%) had wound regeneration in control group and none of them had healthy tissue in both the groups.

Within the experimental, the effectiveness of papaya pulp dressing was analyzed by paired t test revealed that there was a difference in the pre-test (26.37±7.73) and post-test (51.10±6.81) mean value in the experimental group and found statistically significant at the level of $p < 0.001$ revealing that the intervention is beneficial in wound healing. Unpaired t test was used to compare the level of wound healing between the control and experimental group revealed the post-test mean 53.03 with 8.51SD, whereas in control group it was 26.73 with SD of 7.73. It was also proved that there was statistically ($p < 0.001$) significant difference between the experimental and control groups in level of wound healing.

Chi-square test reveals that the post-test level of wound healing is significantly associated with the site of ulcer in clinical

variables of experimental group at the level of $p < 0.05$. It shows that wound healing is highly effective in foot than the other site such as forefoot and ankle.

DISCUSSION

The management of patients with diabetic foot ulcer is complex to plan for a proper care. The primary and ideal responsible for nurses assessing the wound healing in order to provide the effective services to avoid amputations and promote wellbeing of the patients with diabetic foot ulcer. Standardizing the procedure for measurement of diabetic foot ulcer is crucial to evaluate whether the wound is moving towards desired outcomes. Consistent and accurate measurements of length and width aid in reliable tracking of wound closure progress.

The present study finding revealed that in the pretest almost more than 80% of them had wound regeneration and none of them had healthy tissue in both experimental and control group, which shows that patients who were admitted with diabetic foot ulcer having same score. If left untreated, diabetic ulcers can lead to severe infections and amputation. The frequency and severity of wound infections is increased in diabetes due to high glucose level, impairment of granulocytic function. The factors that influence the healing of diabetic foot ulcer are poor oxygenation, hospital acquired infections, age, stress, systemic hypertension, poor diet pattern, alcohol consumption, smoking etc. Monthly around 95 to 105 diabetic patients getting admitted in wound degeneration status in Saveetha Medical College and Hospital due to poor knowledge of management. They are staying long time in the hospital for treating diabetic foot ulcer due to poor knowledge of managing diabetes, improper diet, associated illness, and the cost of treatment which is not affordable by them and their length of hospitalization also prolonged. This findings supported by the study which showed that 83.3% of diabetic clients were having wound degeneration in the pretest, due to high blood sugar, poor circulation, nerve damage, and poor management of diabetes.¹² Another study consistent with the present study finding, that all of them had wound degeneration due to high blood sugar and poor dressing management in the hospital.¹³

The present study intensively analyzed with papaya pulp dressing and observed that there is an improvement in the experimental group who had received the papaya pulp dressing whereas in the control group who had routine care had no improvement in the level of wound healing. The findings of the present study was supported by the study Mehjabeen Fatimah et al, who revealed that the fresh raw grated papaya with skin and latex dressing decrease the duration of healing probably due to enzymatic micro debridement and antibacterial activity.¹⁴ Similarly, Vasuki et al, also reported that papaya dressing plays an important role in management of chronic non-healing ulcer.¹⁵ Another study conducted by Ihtasham Muhammad Ch et al, who concluded that topical papaya dressing provides cost effective and favorable outcome in patients with diabetic foot ulcer by decreasing the healing duration, reducing surgical interventions in the experimental group than the control group.¹⁶ This denotes that papaya has the action of antibacterial activity and it promotes rapid wound healing by de-sloughing and granulation of tissues with an ability to dissolve dead tissue due to papaya contain enzymatic micro debridement and antibacterial activity.¹⁷

The findings of the present study observed that the clinical variables of site of ulcer had shown statistically significant association with post-test level of wound healing among patients with diabetic foot ulcer in the experimental group. Wound healing is highly effective in the foot than the other site such as forefoot and ankle. This was supported by study revealed that foot is highly associated with post-test level of wound healing due to

poor foot care and walking with bare feet¹⁵ which was contrast to the present study findings. The investigation of the wound culture is limited to the present study.

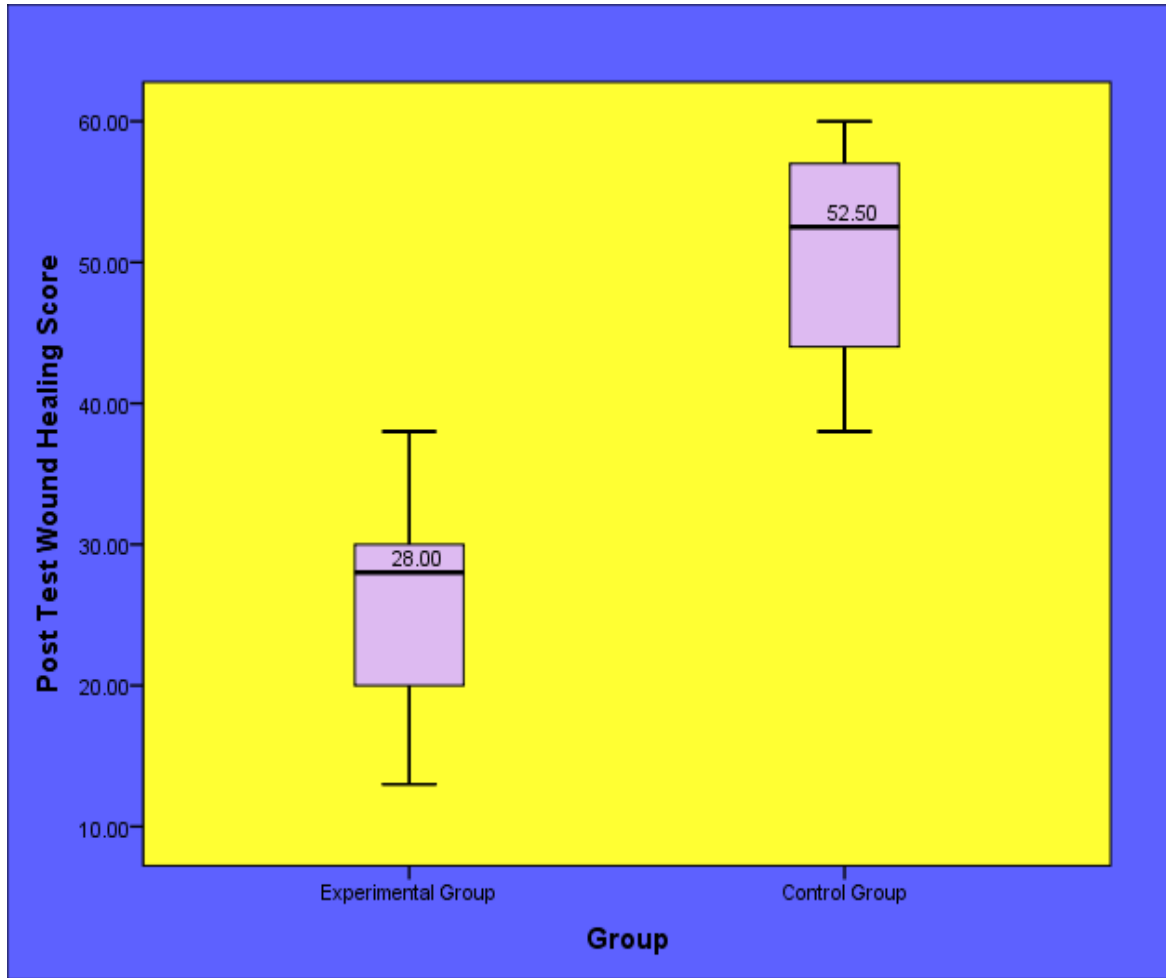


Figure 1: Comparison of post-test level of papaya pulp dressing on wound healing of patients with diabetic foot ulcer between the experimental and control group.

Table 1: Effectiveness of papaya pulp dressing on wound healing of patients with diabetic foot ulcer in experimental group

Wound Healing of diabetic foot ulcer	Mean	S.D	paired 't' Value
Pre-test	26.37	7.73	t = 13.146
Post-Test	51.10	6.81	p = 0.001 S***

***p<0.001, S – Significant

CONCLUSION

The study findings concluded that Papaya pulp dressing is useful to improve the wound healing of diabetic foot ulcer and it is very effective in healing of ulcer in the foot than the other site of ankle and fore foot among patients with diabetic foot ulcer. Papaya pulp dressing can be practiced in the hospital to treat the patients with diabetic foot ulcer which improves the wound healing and

reduces the burden of the patients by cost and prolong hospitalization and improves the quality of life of patients.

ACKNOWLEDGEMENT

The authors would like to thank all the patients for participating in this research study and also thank the surgeon and nursing staff of the surgical ward for their support to complete the study successfully.

REFERENCES

1. Lauterbach S, Kostev K, Kohlmann T. Prevalence of diabetic foot syndrome and its risk factors. *J wound care*, 2010; 19(8): 333-337.
2. Katsilambros N. Implementation and effectiveness of the first community lifestyle intervention program to prevent Type 2 diabetes. *Diabet Med*, 2010; 27(4) 459-465.
3. Moxey PW. Diabetes and lower-limb amputations in the community. *Diabetes care*, 2011; 21(5):738-743.
4. Tesfamichael G, Mariam, Abebaw Alemayehu, Eleni Tesfaye, Worku Mequannt, Kiber Temesgen, Fisseha Yetwale, et al. Prevalence of Diabetic Foot Ulcer and Associated Factors among Adult Diabetic Patients Who Attend the Diabetic Follow-Up Clinic at the University of Gondar Referral Hospital, North West Ethiopia, 2016: Institutional-Based Cross-Sectional Study. *J Dia Res*, 2017;2017:1-8.
5. Prompers L, Huijberts M, Apelqvist J, Jude E, Piaggese A, Bakker K, Edmonds M, et al. High prevalence of ischaemia, infection and serious comorbidity in patients with diabetic foot disease in Europe. Baseline results from the Eurodiale study. *Diabetologia*, 2007; 50(1):18-25
6. Benotmane A1, Mohammedi F, Ayad F, Kadi K, Azzouz A. Diabetic foot lesions: Etiologic and prognostic factors. *Diabetes Metab*, 2000; 26(2):113-7.
7. Kshitij Shankhdhar, Lakshmi Kant Shankhdhar, Uma Shankhdhar, Smita Shankhdhar. Diabetic foot problems in India: An overview and potential simple approaches in a developing country. *Current diabetes report*, 2008; 8(6): 452-457.
8. Al-Rubeaan K, Al Derwish M, Ouizi S, Youssef AM, Subhani SN, Ibrahim HM, et al. Diabetic foot complications and their risk factors from a large retrospective cohort study. *PLoS One*, 2015; 10(5).
9. Sakir Ozgur Keskek, Sinan Kirim, Necmettin Yanmaz. Estimated costs of the treatment of diabetic foot ulcers in a tertiary hospital in Turkey. *Pak J Med Sci*, 2014; 30(5): 968–971.
10. Tae Gyun Kim, Sang Young Moon, Moon Seok Park, Soon-Sun Kwon, Ki Jin Jung, Taeseung Lee, et al. Factors Affecting Length of Hospital Stay and Mortality in Infected Diabetic Foot Ulcers Undergoing Surgical Drainage without Major Amputation *J Korean Med Sci*, 2016 J; 31(1): 120–124.
11. Mohamed Abd Elgadir, Mohamed Salama, Aishah Adam. *Carica papaya* as a source of natural medicine and its utilization in selected pharmaceutical applications. *Int J Pharm Sci*, 2014; 6 (1): 868-871.
12. Geethalakhmi. Assess the effectiveness of papaya dressing on diabetic foot ulcer among clients admitted in diabetology ward at Rajiv Gandhi Government General Hospital, Chennai. repository-tnmgrmu.ac.in/146/2017.
13. A.Velmurugan. Papaya dressings in the management of diabetic foot at St. John's College of Nursing, Idukki, Kerala. *IDC International journal*, 2014.
14. Mehjabeen Fatimah, Saiyad Shah, Alam, Hamiduddin. Importance of raw papaya dressing in diabetic foot ulcer – A case report. *European Journal of Bio-Medical and pharmaceutical Sciences*, 2015; 2(3): 505-508.
15. Vasuki V, Thanmaran NB, Vimalakaran B, Madan KA. Comparative study of papaya dressing versus normal saline dressing in healing of diabetic foot ulcers. *Int Surg J*, 2017; 4(4):1209-1216.
16. Ihtasham Muhammad Ch, Shaukat Ali Shaikh, Haroon ur Rashid. Assess the role of papaya dressings in the management of diabetic foot in terms of healing of ulcers. *Journal of Rawalpindi Medical College*, 2014; 18(1): 87-89.
17. Bapurapu Rajaram, Madipeddi Venkanna, Boda Kumaraswamy, Dodda Ramesh Kumar, Sridhar, Reddy Patlolla et al. Determine the role of grated papaya fruit dressings in the management of diabetic foot ulcers. *Journal of Evidence based Medicine and Healthcare*, 2015; 2(42): 7365-7371.

Cite this article as:

S.Indumathy et al. Effectiveness of papaya pulp dressing on diabetic foot ulcer. *Int. J. Res. Ayurveda Pharm.* 2018;9(5):75-78
<http://dx.doi.org/10.7897/2277-4343.095160>

Source of support: Nil, Conflict of interest: None Declared

Disclaimer: IJRAP is solely owned by Moksha Publishing House - A non-profit publishing house, dedicated to publish quality research, while every effort has been taken to verify the accuracy of the content published in our Journal. IJRAP cannot accept any responsibility or liability for the site content and articles published. The views expressed in articles by our contributing authors are not necessarily those of IJRAP editor or editorial board members.