Research Article

www.ijrap.net

(ISSN Online:2229–3566, ISSN Print:2277–4343)

EVALUATION OF WOUND HEALING POTENTIAL OF YASHADAMRITA MALHARA IN DIABETIC WOUND MODELS

Mayuri Shailesh Ganatra [1]*, Vaishali Khobragade [2]

[1] PG Scholar, Department Rasashastra and Bhaishjya Kalpana, Y.M.T. Ayurvedic Medical College and Hospital, Kharghar, Navi Mumbai, India

[2] Lecturer, Department Rasashastra and Bhaishjya Kalpana, Y.M.T. Ayurvedic Medical College and Hospital, Kharghar, Navi Mumbai, India

Received on: 11/07/22 Accepted on: 17/08/22

***Corresponding author**
E-mail: mayuriganatra25@gmail.com

DOI: 10.7897/2277-4343.1305123

ABSTRACT

Due to unclear aetiology, the healing impairment of diabetic patients is still a severe clinical problem for physicians worldwide. Hence impaired wound healing in diabetes has caught the attention of the world to help promote the healing process and prevent rising complications. The present study was designed to investigate the comparative wound healing efficacy of Yashadamrita Malhara with standard formulation, i.e., Framycetin Sulphate, using excision wound models in Diabetic rats. Streptozotocin (50 mg/kg, IP) induced diabetic rat model was used to evaluate the wound healing effect of Yashadamrita Malhara in comparison to Framycetin sulphate. Yashadamrita Malhara was applied for 12 days. Wound contraction % and estimation of hydroxyproline, collagen and hexosamine were studied. Obtained data were analyzed statistically. On the 12th day, there were no positive changes in the wound area contraction of the Yashadamrita Malhara treated group compared to the Framycetin sulphate treated group. The histopathology reports also showed no healing in the test drug group. Yashadamrita Malhara did not show any statistically significant Vrana Ropana (wound healing) activity in Diabetic Rats.

Keywords: Yashadamrita Malhara, Vrana, Ropana, Diabetic Wound, Framycetin sulphate.

INTRODUCTION

Wounds are physical injuries which lead to open or broken skin, and thus the appropriate method of wound healing is essential for the restoration of disrupted anatomical stability and disturbed functional state of the skin. [1] Repair of injured tissues occurs as a sequence of events, which includes inflammation, proliferation and migration of different cell types.[2] Though the healing process takes place by itself and does not require much help, various physiologic and mechanical factors such as poor nutrition, insufficient oxygenation, infection, prolonged inflammation, age, diabetes and other diseases, drugs, smoking, alcoholism, depression and other disorders, drugs, smoking, alcoholism, depression ad other factors may impair healing response, resulting in a chronic wound that fails to proceed through the usual stepwise progression.[3] Different approaches have been adopted in treating diabetic wounds, and herbomineral drugs are certainly one of those approaches that have drawn global attention. Diabetic wounds are slow to heal, are difficult to manage and could last for weeks, posing a severe challenge to manage in a clinical setting. The exact pathogenesis of poor wound healing in the diabetic wound is not adequately understood. However, human and animal studies show impairment in different phases of the wound healing process.[4] Nowadays, new therapeutic approaches for acute and long-term wound management are accentuated to reduce the wound burden and better understand the physiology of healing and wound care.[5] The aim of treating wounds is to shorten the healing time and reduce the risks of undesired complications.[6]

India has a rich tradition of plant-based knowledge in healthcare. Many Ayurvedic plants and minerals have a vital role in wound healing. A large number of plants, plant extracts, decoctions or pastes are equally used by trial and folklore traditions in India to treat cuts, wounds and burns.[7] The natural agents induce healing and regeneration of the lost tissue by multiple mechanisms such as coagulation, disinfection, debridement, and antioxidant and provide a suitable environment for the natural healing process.[8] Yashada and its formulations like Yashada Bhasma plays a significant role in protein synthesis, cell division and wound healing. It is known to have antiseptic and astringent properties also predominant in Katu, Kashaya rasa and Sheeta Guna, thus having action of Kapha Pitta Shamana.[9] It also improves the binding power of the cells of soft skin tissues, enhances cell migration and regeneration, and hastens wound healing.[10]

This study aimed to investigate the efficacy of a new formulation of Yashada Bhasma, i.e., Yashadamrita Malhara, on the healing of excision wounds in Diabetes induced Wistar Rats.

MATERIALS AND METHODS

Preparation of Formulation

The raw materials were obtained from the local market, and each raw material was authenticated. The test drug, i.e., Yashadamrita Malhara (YM), was prepared as per the classical reference mentioned in Rasatarangini in the college laboratory. YM was prepared by triturating three parts of Sikta Taila with 1 part of Yashada Bhasma in a Khalvayantra.[11] Framycetin Sulphate cream was purchased from the local market.

Animals

Wistar rats weighing 200-250 gm were used for the study. The animals were produced from APT Testing and Research Pvt Ltd, Pune. The rats were housed in their cages for five days before the start of dosing in the experimental room after the veterinary examination. Room temperature maintained between 22±3 ^{0}C, relative humidity 50-60 % and illumination cycle set to 12 hours light and 12 hours dark. The animals were fed a standard pellet diet and were provided water ad libitum. The Institutional Animal Ethics Committee (RP08/2122/22/May/2021) approved all experimental protocols.

***In Vivo* Evaluation of Wound Healing Activity**

Induction of Diabetes- Initially, 24 rats were given Streptozotocin (STZ) 50 mg/Kg IP (intraperitoneal) to induce diabetes; after 78 hours of STZ injection, blood glucose levels were determined to confirm diabetes. Animals with non-fasting blood glucose levels more than or equal to 300 mg/dl were considered to have diabetes and were selected for the study.

Grouping of Animals- Animals were randomized into four groups of six animals each, i.e., Normal Wound Control (NWC), Disease Wound Control (DWC), Standard group (FS), and Test group (YM). The animals of groups 3 and 4 were treated with Framycetin Sulphate and Yashadamrita Malhara, respectively, whereas no treatment was given to group 1 (NWC) and group 2 (DWC).

Excision Wound Model- The Rats were anaesthetized by injecting ketamine hydrochloride and xylazine intramuscularly in 1:1 proportion. The dorsal fur of the animals was shaved with a shaving machine. The wound area to be created was marked on the back of the animals by a Marker using a circular stencil. A circular excision wound of 300 to 350 mm^2 was created to total thickness along the markings using toothed forceps and pointed scissors. Test samples and Standard drugs were topically applied to the respective groups, as shown in the following table, for 12 days. Wound areas were measured on 0, 3rd, 6th, 9th, and 12th day for all groups, using a transparency sheet and a permanent marker. The measurement was done using graph paper, and the entire wound was kept open.

At the end of the study, skin tissue was harvested and analyzed for hydroxyproline, collagen and hexosamine. Sample tissues were fixed in 10% formalin for histopathology.

Table 1: Rats Were Divided into the Following Groups

Groups	Specifications	Treatment Specification
1	Normal wound control (NWC)	No treatment
2	Disease wound Control (DWC)	Streptozotocin (STZ) 50mg/Kg IP
3	Standard group (FS)	Streptozotocin (STZ) 50mg/Kg IP + Framycetin Sulphate (FM)
4	Test group (YM)	Streptozotocin (STZ) 50mg/Kg IP + Yashadamrita Malhara (YM)



Figure 1: Material and Methods

Statistical Analysis

Because of the sample size limitation, non-parametric tests have been used for comparisons. Inter-group comparison (>2 groups) was made using Kruskal Wallis ANOVA, followed by a pair-wise comparison using the Mann-Whitney U test. For all the statistical tests, $p<0.05$ was considered statistically significant, keeping α error at 5% and β error at 20%, thus giving power to the study as 80%.

RESULTS AND DISCUSSION

The body weight was measured weekly. There was a statistically significant change in body weight of DWC, Standard (FS) and Test (YM) group animals compared with NWC animals on day 0 and day 7. Body weight was significantly increased in the STD group compared with the TEST group. Uncertain death of some rats from each group except NWC was observed during the study, possibly because of STZ-induced diabetes. Also, there was no specific diabetic diet or any internal anti-diabetic medicine given to the animals, which may have caused increased blood sugar levels, thus causing more severity of the disease.

The effect of wound healing activity in this model was evaluated by determining the per cent wound contraction and levels of hydroxyproline, hexosamine and collagen. Histopathology of skin tissue was also evaluated at the end of the study.

Table 2: Results of % Wound Contraction, % of Hydroxyproline, % of Hexosamine and % of Collagen

S. No.	Groups	Parameters			
		Wound Contraction %	Hydroxyproline %	Hexosamine %	Collagen %
1	NWC	89	NA	NA	NA
2	DWC	NA	48	35	48
3	STD (FS)	70	84	80	84
4	TEST (YM)	NA	43	21	43

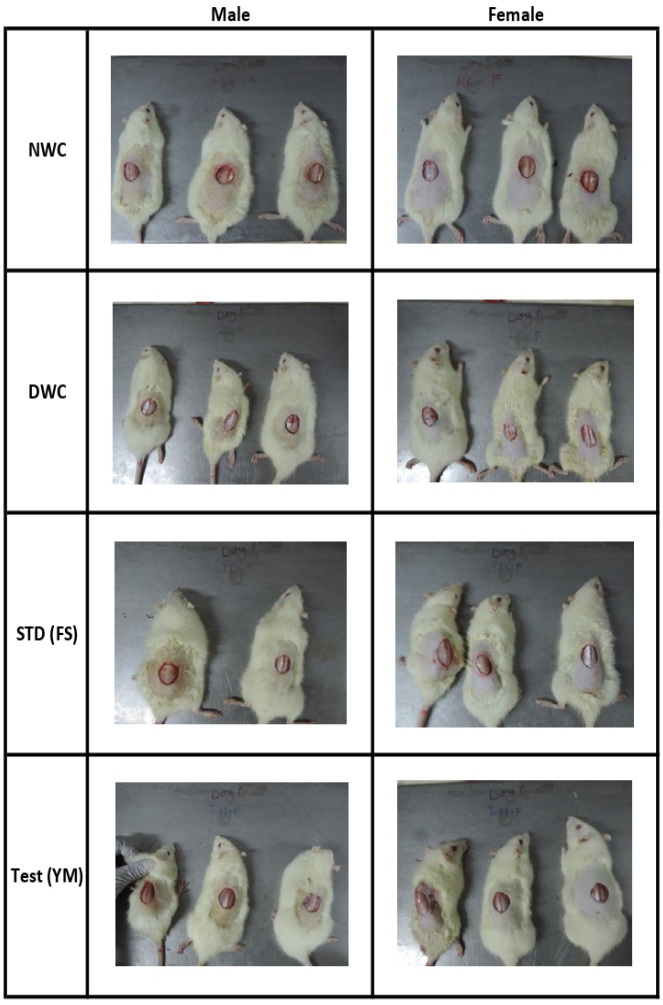

Figure 2: Day 0

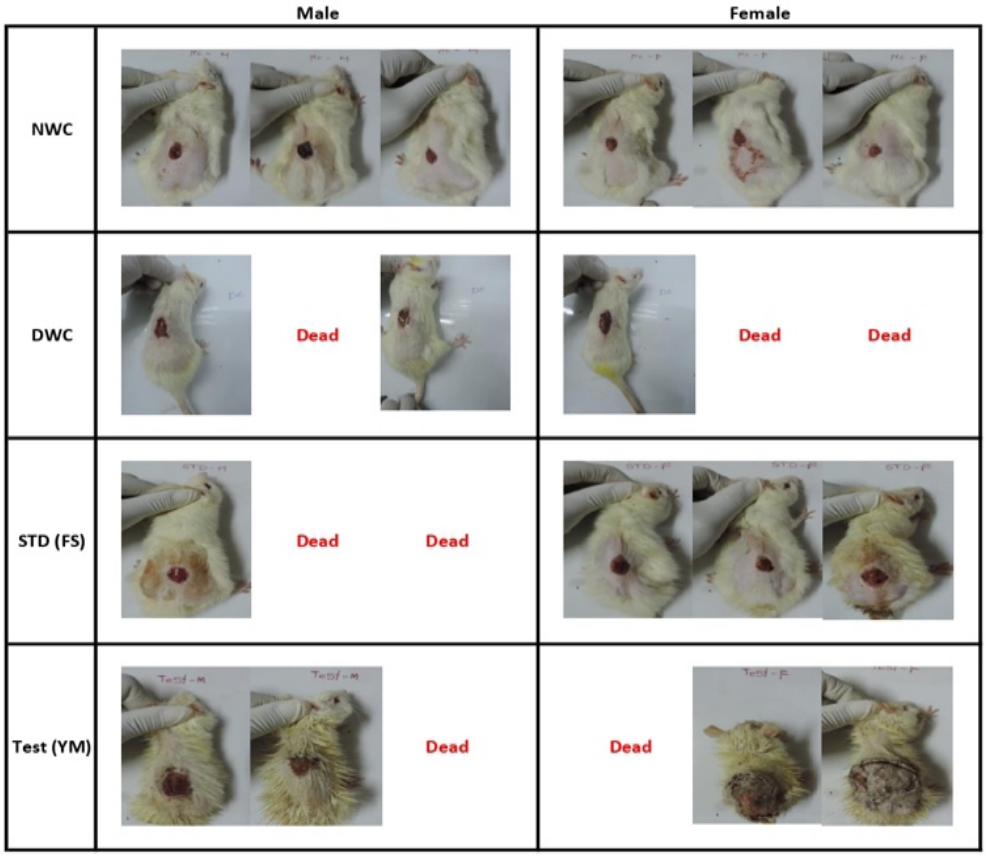

Figure 3: Day 12

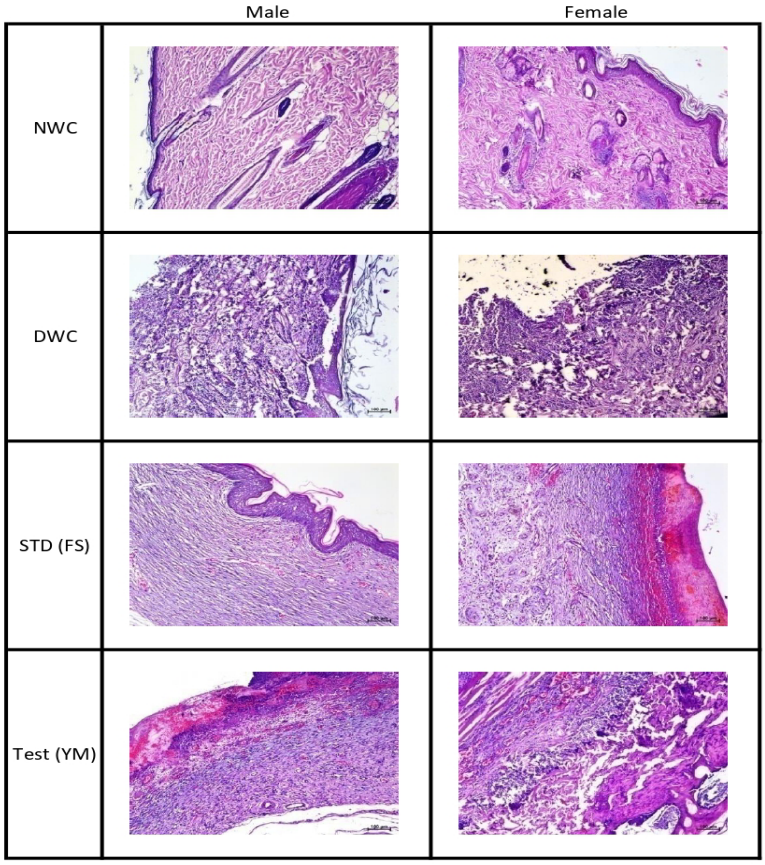

Figure 4: Histopathology Images

The wound area was measured on days 0, 3, 6, 9, and 12 of the experiment. There was no change in the wound areas of all groups on day 0 and day three compared with the DWC group. On day 12, the wound areas were significantly decreased in the Standard group (FS) compared to the DWC group. While in the Test group (YM), no positive changes were observed in the wound area contraction, which was not statistically significant. The studies on the excision wound model revealed that the test drug group (YM) did not show any decreased wound area from day 0 to day 12. The per cent wound contraction was calculated compared with the respective groups' wound area on day 0. The per cent wound contraction was found to be 89 % in NWC and 70% in the FS group, whereas in the DWC group, there was a contraction in the wound area of 2 rats and expansion in the wound area of a rat and test drug (YM) group there was a contraction in wound area of 2 rats and expansion in wound area of 2 rats. Thus, it statistically shows no significant results compared to the STD (FS).

At the end of the study, the tissue from the wound area was harvested and studied for hexosamine, hydroxyproline and collagen. The hexosamine content was found to be 35% in DWC, 80% in the FS group and 21 % in the YM group compared with the NWC group. Hydroxyproline levels were 48% in the DWC group, 84% in FS and 43% in YM compared with the NWC group. Similarly, Collagen content was also found to be 48% in the DWC group, 84% in FS and 43% in YM compared with the NWC group. The hexosamine, hydroxyproline and collagen levels were lower in the test drug group YM than in the Standard drug group FS.

The skin tissue sections in the dermis and subcutaneous tissue showed the presence of multiple foci with infiltration of mononuclear inflammatory cells and congested blood vessels. Moderate haemorrhages in the dermis (epithelial) region and mild hyperkeratosis in the epidermis region were noted, thus suggesting incomplete healing of skin epithelium. Histopathology of skin tissue showed no signs of recovery in Test drug (YM) treated animals compared to Standard drug (FS) treated animals.

CONCLUSION

Based on the wound measurement area results, % wound contraction, levels of hexosamine, collage and hydroxyproline and histopathology of skin tissue Yashadamrita Malhara did not show any signs of healing in the wounds.

REFERENCES

1. KC Haritha Yadav, J Ravi Kumar, S Ilias Basha, GR Deshmukh, Ravi Gujjula and B Santhamma. Wound healing activity of topical application of *Aloe vera* gel in experimental animal models. International Journal of Pharma and Bio Sciences. 2012; 3:63-72.
2. S Murthy, MK Gautam, Shalini Goel, V Purohit, H Sharma and RK Goel. Evaluation of *In-Vitro* wound healing activity of *Bacopa monnieri* on different wound healing models in rats. Hindawi Publishing Corporation Bio Med Research International. 2013; DOI: http://dx.doi.org/10.1155/2013/972028
3. Nehete MN, Nipanikar S, Kanji Lal AS, Kanji Lal S, Tatke PA. Comparative efficacy of two polyherbal creams with Framycetin Sulphate on diabetic wound model in rats. Journal of Ayurveda and Integrative Medicine. 2016; 7:83-7. DOI: http://dx.doi.org/10.1016/j.jaim.2015.09.004
4. Oluwafemi OO. Medicinal plants and their effects on diabetic wound healing. Veterinary World. 2019, 12(5): 653-663. DOI: www.veterinaryworld.org/vol.12/May-2019/5.pdf
5. Sandesh R Wayal, Shailendra S Gurav. Evaluation of wound healing potential of Bahallatakadi Ghrita - Cow ghee-based polyherbal formulation *in-vivo* excision and incision wound model. J Complement Integer Med 2021; 1-9. DOI: https://doi.org/10.1515/jcim-2020-0179
6. Qi Zeng, Hui Xie, Hongjin Song, Fayu Nie, Jiahua Wang, Dan Chen *et al*. *In vivo* wound healing activity of *Abrus Cantoniensis* Extract. Hindawi Publishing Corporation. Evidence-Based Complementary and Alternative Medicine. 2016. DOI: http://dx.doi.org/10.1155/2016/6568528
7. Kumar B. Vijayakumar M, Govindarajan R. Pushpangadan P. Ethnopharmacological approaches to wound healing - exploring medicinal plants of India. J Ethnopharmacol.2007; 114:103-13. DOI: https://doi.org/10.1016/j.jep.2007.08.010
8. Priya KS, Gnanamani A, Radhakrishnan N, Babu M. Healing potential of *Datura alba* on burn wounds in albino rats. Journal of Ethnopharmacology. 2002; 83:193-9. DOI: http://doi.org/10.1016/SO378-8741(02)00195-2
9. Gnani VR, and Savadi BS. A comparative clinical study on the application of Yashada Bhasma Lepa and Jatyadi Ghrita in the Management of Dushta Vrana W.S.R. Diabetic Ulcer. International Journal of Ayurveda and Pharma Research. 2019; 7:1-9.
10. Patil Pravin, Nagore Dheeraj, Ambikar Digambar, Patil Manohar, Nipanikar Sanjay, Kanji Lal *et al*. Evaluation of wound healing potential of various wound healing creams in fresh, diabetic and burn wound models. European Journal of Pharmaceutical and Medical Research. 2019; 3:248-258.
11. Sadanand Sharma (11th edition 1979, Reprint 2019) Rasatarangini with Prasadane Vyakhya of Hari Dutta Shastri and Rasa Vidynana Hindi commentary by Ayurveda Acharya Pandit Dharmanand Shastri, Motilal Banarsidas, Delhi. P 483-484.

Cite this article as:

Mayuri Shailesh Ganatra and Vaishali Khobragade. Evaluation of wound healing potential of Yashadamrita malhara in diabetic wound models. Int. J. Res. Ayurveda Pharm. 2022;13(5):58-62 http://dx.doi.org/10.7897/2277-4343.1305123

Source of support: Nil, Conflict of interest: None Declared