



A CASE DISCUSSION ON OZENA

Angadi.Savita.S.^{1*}, Kotrannavar.Vijaykumar.S.²

¹Asst Prof Dept. of Shalakya Tantra, KLEU Ayurveda Mahavidyalaya, Belgaum, Karnataka, India

²Asst Prof Dept. of Rasashastra, KLEU Ayurveda Mahavidyalaya, Belgaum, Karnataka, India

Received on: 10/03/12 Revised on: 18/04/12 Accepted on: 30/04/12

*Corresponding author

Dr. Savita. S. Angadi. M.S (Ayu), Assistant Professor, Dept of Shalakya Tantra, K.L.E. University's Shri. B.M.K. Ayurveda Mahavidyalaya Shahapur, Belgaum-590003 Karnataka, India Email: savita.angadi@yahoo.com

ABSTRACT

Ozena is a disorder of the nasal mucosa in which the sides of the nasal cavity become atrophied with the production of an offensive smell and crusts. There are number of causes and different treatment modalities available for this condition. After the treatment, symptoms of this disease are reduced but sometimes end up in permanent loss of smell and impairment of taste as a result of this disease. In classics of Ayurveda this ailment was described as Putinasa (Ozena) under the heading of nasagata vyadhis (nasal diseases). Nasya (administration of medicated oil into the nasal cavity) is one of the major treatments for Urdhwajatrugata rogas (diseases of head & neck) explained by Brihatrayees (Charak, Sushruta & Vaghbata). Clinical observation has shown its effectiveness in the treatment of Ozena (Putinasa). A case report of 8 years old male who presented with complaints of foul smell from nose, muco-purelent nasal discharge, nasal obstruction and excoriation of skin of the nasal vestibule has been presented here.

Key words: Putinasa, Ozena, Nasya

INTRODUCTION

Ozena is a special form of chronic atrophic rhinitis, one of the nose diseases which were found back to the 1800's. It is characterized by intranasal crusting, atrophy of the nasal mucous membrane and a fetid odor. It may follow chronic inflammation of the nasal mucosa. The treatment of Ozena in the modern medical science include: Nasal irrigation and removal of crusts using alkaline solutions, application of 25% glucose in glycerin to the nasal mucosa to inhibit the growth of foul-smelling proteolytic organisms, Local antibiotics, such as Chloramphenicol (Kemicetine), Systemic streptomycin and Surgical interventions include: Transposition of parotid duct to maxillary sinus or nasal mucosa.

In Ayurveda it can be taken as Putinasa, one of the nasagata roga which is having the main symptom as foul smell from the nose and mouth¹. The main treatment of nasagata rogas as well as urdhwajatru rogas is nasya. As the root cause lies in the urdhwajatrubhaga and the treatment of choice for that is nasya as Vaghbhata quoted that "nasaa hi shiraso dhwaram tena tadvyapaaya hanti taana"² hence nasya was selected as treatment of choice to combat the root cause of Putinasa. This case showed the good results.

Case report

An 8 years old male presented with the complaints of foul smell from nose, muco-purelent nasal discharge and nasal obstruction on/off from two years now. The patient also complained of excoriation of skin of the nasal vestibule once in every 15-20 days.

On examination

A foul smell was present with a thick muco-purelent nasal discharge, mucosal crusting and mild deviation of nasal septum along with excoriation of skin of the nasal vestibule. There was slight tenderness over the tip of the nose. Routine hematology (Hb, TC, DC and ESR) investigations was done. Hemoglobin% was reduced and ESR was increased.

Past history

Patient had taken nasal irrigation with alkaline solution & crusts were removed once in a 15 days for 6 months in 2009. After discontinuation of therapy, the condition was relapsed with frank Ozena.

Procedures administered to the patient

The patient was administered with Navan Nasya once daily for seven consecutive days. The details of the procedures are described in Table-1.

Before starting the Nasya, Shatdhauta ghrita was applied over the excoriation of skin of the nasal vestibule twice daily along with internal medication Vyoshadi vati one tablet thrice daily for 8 days and it was cured.

Table 1: Procedure of Nasya

Poorvakarma (Prerequisite procedure)	Mukhabhyanga (face massage) with Murchita tila taila
	Nadi Swedana (Sudation therapy)
Pradhanakarma (Main procedure)	Instillation of 6 drops of Shad bindu taila in each nostril
Pashchatakarma (Post procedure)	Dhumapana with Haridra varti Kavala with Triphala kashaya

Patya -advised to take laghu supachya ushna ahara

Apatya -advised not to take head bath, cold water, takra, dadhi, sheeta ahara

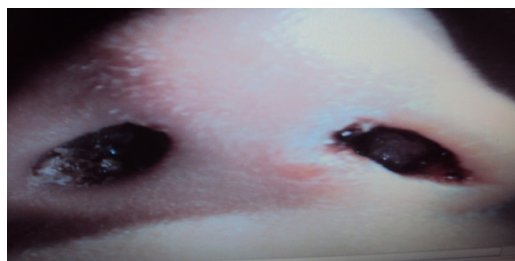
RESULTS

The features of vestibulitis disappeared by 8 days. After completion of one course Nasya the foul smell from the nose was completely disappeared with mild nasal obstruction. The patient was prescribed oral medication viz Haridra khanda 1/2 tsp with milk twice daily and Chitraka Haritaki 1/2 tsp twice daily for one month and advised to follow the Patya ahara.

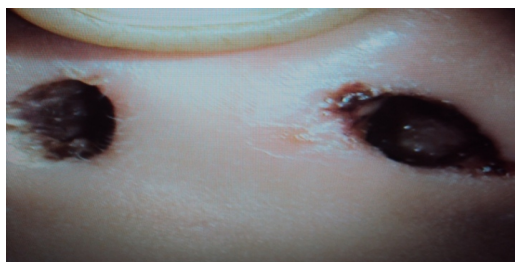
DISCUSSION

Foul smell from nose is characteristic feature of Ozena. Normal nasal mucosa is lined with pseudo stratified columnar epithelium and has abundant mucous and serous glands. In atrophic rhinitis the epithelial layer undergoes squamous metaplasia and subsequent loss of cilia. Glands

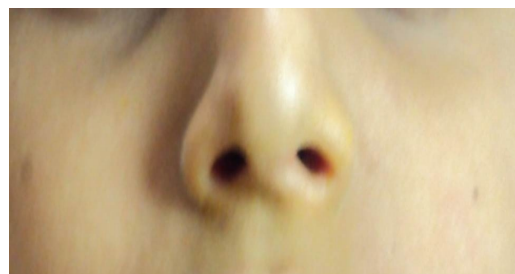
and goblet cells become fewer. The endarteritis of blood vessels causes diminished blood supply to the mucosa. As a result of the loss of ciliated epithelium, thick viscid secretions of the nose get stagnated and results in secondary infections and crust formation.³



Picture 1: Before Treatment



Picture 2: Before Treatment



Picture 3: After Treatment

Mode of action

Deepana and Pachana oushadhi

Oral administration of the medicines in the form of Powder, tablet or decoction enhance the digestive power that renders the pakwa state of the morbid doshas, so that later it may be expelled easily by nasya treatment.

Mukhabhyanga

It increases the blood circulation and helps in mobilization of the doshas from the site of morbidity to the site of elimination.

Nadi sweda

This procedure of sweating also helps in elimination of doshas from the affected part in to the nose from where it is removed by the Nasya.

Shodhana type of Navana Nasya

In this procedure the doshas collected in the urdhwanga will be expelled out through the nose. Here sneha dravyas used for Navana Nasya⁴ are having properties like drava, sukshma, sara, snigdha and guru, because of these properties the drug gets absorbed in to the nasal mucosa and helps in removal of doshas. It also does the santarpana of tissues, makes the tissues snehakrut, mardavakrut and balakrut.

Pathway of Nasya drug → nasal cavity → olfactory epithelium → olfactory nerve → cribriform plate of ethmoid bone → anterior cranial fossa → medial and lateral olfactory area of cerebral cortex.

The chemical impulse which is generated by Nasya finally converts into neuronal impulse and influences on cerebral cortex area and there by producing a stimulatory effect resulting in evacuation of doshas.

Paschata karma (post operative)

Kavala and Dhumapana help to remove the residual doshas after Nasya karma. These procedures clear the passages of nose and throat by removing the kaphadosha.

CONCLUSION

Ozena is a disease which not only affects the body but it also produces mental depression. There was classic description of the disease was given by Dr. Frank Bosworth in 1881, who noted “ the breath is often so penetrating as to render the near presence of the sufferer not only unpleasant but almost unendurable”⁵. So in such a disease Ayurvedic line of management shows excellent results, by reaching the two main goals of the therapy, one restoration of nasal hydration and second is minimization of crusting and debris.

REFERENCES

1. Shastri Ambhikadatta, Sushruta Samhita of Maharshi Sushruta with Ayurveda tattva Sandipika Hindi Commentary, Uttara tantra, Nasaroga Vijnaniya Adhyaya, shloka no 7, 16th edition 2003, Choukambha Sanskrit Sansthan Varanasi, pp. 106
2. Kaviraj Atridev Gupta, Astanga Hrudaya of Acharya Vagbhata, with Vidhyotini Hindi commentary, Sutra Sthana, Nasya vidhi Adhyaya, shloka no 1, reprint 2005, Choukambha Sanskrit Bhavan Varanasi, pp. 127
3. Dr. Mohammad Maqbool, Text book of Ear, nose & throat diseases, Jaypee Brothers
4. New Delhi, Reprint 1997, pp. 260
5. Shri Pandit Lalachandra Shastri vaidya, Astanga Sangraha of Acharya Vagbhata, with Sarvanga Sundari Teeka, Sutra Sthana, Nasya vidhi Adhyaya, shloka no 8, 4th edition 1996, Shri Baidyanath Ayurveda Bhavan .Nagapur, pp. 812
6. Chronic Atrophic Rhinitis (Cited on 21/09/2011) available from www.wikipedia.com/AtrophicRhinitis.

Source of support: Nil, Conflict of interest: None Declared