



## Research Article

www.ijrap.net



### ACUTE TOXICITY OF THE AQUEOUS EXTRACT FROM *BRILLANTAISIA VOGELIANA* (NÉES) BENTH. (ACANTHACEAE)

Aimé Valère SOH OUMBE<sup>1\*</sup>, Constant Anatole PIEME<sup>2</sup>, Amadou FEWOU<sup>3</sup>, Mathieu NDOMOU<sup>4</sup>, Jeanne NGOGANG YONKEU<sup>2</sup>

<sup>1</sup>Department of Biochemistry, Faculty of Sciences University of Yaoundé I, P.O.Box 812 Yaoundé-Cameroon

<sup>2</sup>Department of Physiological and Biochemical Sciences, Faculty of Medicine and Biomedical Sciences, University of Yaoundé I, P.O.Box: 1634 Yaoundé-Cameroon

<sup>3</sup>Anatomopathology laboratory service, Laquintinie Hospital Douala, P.O.Box 4035 Douala-Cameroon, Faculty of Medicine and Biomedical Sciences, University of Yaoundé I, P.O.Box: 1634 Yaoundé-Cameroon

<sup>4</sup>Department of Biochemistry, Faculty of Sciences University of Douala, P.O.Box 24157 Douala-Cameroon

Received on: 07/12/12 Revised on: 21/01/13 Accepted on: 10/02/13

#### \*Corresponding author

E-mail: sovaloved@hotmail.com

DOI: 10.7897/2277-4343.04214

Published by Moksha Publishing House. Website www.mokshaph.com

All rights reserved.

#### ABSTRACT

*Brillantaisia vogeliana* (Acanthacées) is a plant used in the West-Cameroon traditional pharmacopeia. This species have been used to facilitate deliverance and delivery and to treat stomach ailment. The aqueous extract of leaves was studied by conventional pharmacological methods.

Twelve female rats were randomly assigned in two groups of 6 animals each designated as control and treated groups. After a sighting study, one group of the fasted animals for 12h received a single oral dose of 2000 mg/kg body weight of aqueous solution of *Brillantaisia vogeliana* while control group received distilled water.

Oral consumption of 2 g/kg of *Brillantaisia vogeliana* produced neither mortality nor significant differences in the body and relative organs weights except relative liver weight between control and treated animals. Moreover, no abnormality and no histopathological changes were detectable between both control and treated animals. Hematological analysis showed no difference in any of the parameters tested (WBC count, platelet, total leukocytes, RBC count, hematocrit and hemoglobin estimation) in either control or treated groups. No significant change occurred in the blood chemistry parameters, including creatinine, urea nitrogen (UN), alkaline phosphatase, aspartate amino transferase (ASAT), alanine aminotransferase (ALAT), calcium and phosphorus. However,  $\alpha$ -amylase and total protein showed a significant difference between control and treated groups. The results showed the innocuity of the aqueous extract of *B. vogeliana* and thus validated its utilization in Cameroonian traditional pharmacopeia.

The LD<sub>50</sub> was higher than 2g/kg of body weight and according to Globally Harmonized Hazard Classification and Labelling Scheme (GHS), aqueous extract of *B. vogeliana* was classified in group 5.

**Keywords:** *Brillantaisia vogeliana*, aqueous extract, acute toxicity, acanthaceae

#### INTRODUCTION

During eighties, the World Health Organization noticed that, in both developed and poor countries, the populations have developed interest in phytotherapy because of the constant failure of modern medicine. The non-availability, increasing cost of modern drugs and limited access to adequate health have compelled about 80% of the world population to use traditional pharmacopeia for primary health care especially in the tropical and sub-tropical regions<sup>1</sup>. About 75% of herbal drugs used to treat different human affections have natural origin<sup>2</sup>. Most of these plants used and which are available in local markets have never been formally tested either for their efficacy or for their toxicity<sup>3</sup>. Besides this, the fact that a drug has a natural origin did not assure its innocuity. The use of a medicinal plant on its entire form, maceration, infusion, decoction or the other form can induce some side effects or allergic reactions of short, middle and long term type. One of such plant named *Brillantaisia vogeliana* has the reputation as weight loss plant and used by the people of Bandjoun, western Region of Cameroon<sup>4</sup>. This plant, commonly called “bùbù kouop” by the local people is also used by pregnant women to facilitate the deliverance but its toxicity has been not well investigated. In fact, Keeping the above

information in view, the present study has been undertaken to evaluate the acute toxicity of the aqueous extract of *B. vogeliana* on *wistar* albino rats.

#### MATERIAL AND METHODS

##### Preparation of extract

Leaves of *Brillantaisia vogeliana* were kindly collected from Pr. NGOGANG's garden at Emana quarter of Yaoundé-Cameroon. The plant has been already identified and authenticated in the National Herbarium by Dr Noubissi. In fact, the Acanthaceae family plants are mostly herbs or shrubs comprising about 250 genera and 2,500 species, including twining forms. *Brillantaisia vogeliana* belonging to this family has simple leaves, opposite and decussate; stipules are lacking. The flowers are bisexual, zygomorphic, and usually are associated with conspicuous, often brightly colored bracts. The calyx is usually deeply 4-5 lobed or sometimes is highly reduced with more numerous minute teeth. The corolla is sympetalous, usually 5-merous, mostly zygomorphic, and commonly 2 lipped. The androecium usually consists of 4 didynamous stamens or only 2 stamens adnate to the corolla tube or epigynous zone, alternate with the lobes. The gynoecium consists of a single compound pistil of 2 carpels, a single style, and a superior ovary with 2 locules,

each with usually 2-10 axile ovules in one or two collateral vertical tiers. An annular nectary disk is usually found around the base of the ovary. The fruit is commonly an elastically dehiscent loculicidal capsule. The seed stalk or funiculus of each seed is modified into a hook shaped jaculator or retinaculum that functions in flinging out the seeds during dehiscence<sup>4</sup>.

The collected material was washed and dried for a week at a room temperature and then pulverized and sieved. 2 kg of powder of *B. vogeliana* was prepared in 2,5 litre of boiled water. The mixture was cooled during 24 h at the room temperature and filtered through a Buchner funnel using a paper filter Wattman No. 1. The aqueous filtrate was dried at 38°C in an oven (Air concept FRILABO<sup>®</sup>; model AC 60) until dryness. The crude extract isolated from *Brillantaisia vogeliana* was weighed and stored at 4°C in the fridge (Sharp<sup>®</sup> corporation; model Nice Crystal Gold) for future use.

#### Animals and animals' husbandry

All animals used in this study were purchased from the Faculty of Medicine and Biomedical Sciences of the University of Yaoundé-I Cameroon. The rats were 8 weeks old weighing 155-178g at the onset of dosing. The animals were conditioned for 5 days prior for testing. They were fed with appropriated rodent meal and water *ad-libitum* during the study. The body weight was measured each week.

#### Acute toxicity (OECD 420)

Twelve female rats were randomly assigned in two groups of 6 animals each designated as control and treated groups. After a sighting study, all the animals were fasted for 12h (overnight) prior for administration and a single oral dose of 2000 mg/kg body weight of aqueous solution of *Brillantaisia vogeliana* was administered *per os* using a stainless steel feeding needle. The control group received distilled water. The animals were observed continuously for 3h and continue during 24 h after administering extract to check any physiological and behavioral responses. The number of death in rats was also noted. After 14 days of the experiment, the LD<sub>50</sub> was established according to guidelines of Organization for Economic Co-operation and Development (OECD guidelines No. 420) following the up and down method as described by Stallard and whitehead<sup>5</sup>.

#### Clinical parameters

At the end of the experiment, all rats were fasted 16 h prior for blood collection. Blood samples were collected in EDTA and dry tubes on day 15. EDTA samples were used for the determination of hematological parameters (haematocrit, haemoglobin concentration, erythrocyte, total leucocytes, platelet and lymphocyte). Another aliquot of blood collected in dry tube was centrifuged at 3000 rpm for 5 min with a centrifuge (Rotifix<sup>®</sup> 32A; Hettich Zentrifugen; model Werk-NK). The serum obtained was used for the estimation of biochemical markers such as calcium, phosphorus, alanine aminotransferase (ALAT), aspartate aminotransferase (ASAT), creatinine, total protein, alpha amylase, urea nitrogen and alkaline phosphatase (ALP).

#### Histopathology

Different selected organs (liver, kidneys, lungs, spleen and heart) were quickly removed, washed with cold saline solution and weighed immediately. These organs were preserved in 10% neutral buffered formaldehyde solution. Fixed tissues were sectioned using microtome (Microtom HM 315<sup>®</sup>), stained with hematoxylin and eosin, and examined microscopically for toxicant-induced changes.

#### Statistical analysis

All values are expressed as mean  $\pm$  standard deviation. Analysis of variance (ANOVA) and student's t-test (Sigma-Stat version 3.5) were used for analysis of different between means.  $p < 0.05$  was considered as statistically significant.

#### RESULTS

No death of rats was recorded during the treatment period in either control or treated group with a single 2 g/kg dose of aqueous extract of *Brillantaisia vogeliana*. The animals have shown no changes in general behavior. There were no significant differences ( $p > 0.05$ ) of the body weight as well as organs weight between the control and the treated groups (Tables 1 and 2). The increase in body weight of rats was found in both of the tested and control groups (Table 1). No significant difference was observed in relative organ weight, except the relative liver weight which was significant lower in treated group than control group ( $p = 0.021$ ).

Biochemical markers analysis showed the increase of some parameters (urea nitrogen, alkaline phosphatase, ALAT and ASAT) in the control group. Despite this increasing, these biochemical parameters did not show any significant difference when compared control and treated groups ( $p > 0.05$ ) (Table 3), except, total protein and  $\alpha$ -amylase content which were significantly ( $p < 0.05$ ) high in treated group as compared to control.

Hematological analysis (Table 4) showed no significant differences of the parameters examined between control and treated groups. These parameters showed a slight decrease in treated group except in platelet ( $P > 0.05$ ).

Histopathology examination of tissues on a gross and microscopic did not indicate detectable abnormalities. The architectures of the internal organs examined and their cellular appearance were comparatively remarkable in both groups. Figure 1 shows photomicrographs of liver section. Animals of control (Figure 1a) and treated (Figure 1b) groups show normal liver architecture with portal triad. The Figure 2 shows photomicrographs of kidney section from control (Figure 2a) and treated (Figure 2b) rat with normal kidney architecture. No important architectural modification was observed in both groups of rats. Figure 3 shows photomicrographs of the heart section from control (Figure 3a) and treated (Figure 3b) groups of rat showing normal architecture. Figure 4a and 4b show photomicrographs of lung section from control and treated groups respectively with lung architecture. Figure 5 shows photomicrographs of spleen section of control (Figure 5a) and treated (Figure 5b) groups rat. No structural modification was observed in different groups of rats.

**Table 1: Weight gain in rats following the treatment with aqueous extract of *Brillantaisia vogeliana***

Group	Weights of rats (g)		
	Initial	Final	Gain
Control	167.50 ± 10.61	195.00 ± 21.21	+27.50 ± 10.61
Treated	166.00 ± 10.85	192.67 ± 9.71	+26.67 ± 9.13

Data are expressed as mean ± SEM, n=6

**Table 2: Mean wet organ weight (5g) and organ to body weight ratio (in parenthesis) of *B. vogeliana* treated rats**

groups	Organs				
	Liver	Kidneys	Heart	Lungs	spleen
Control	5.33 ± 0.18 (3.06 ± 0.26)	1.16 ± 0.04 (0.67 ± 0.08)	0.500 ± 0.03 (0.29 ± 0.03)	1.25 ± 0.21 (0.71 ± 0.04)	0.41 ± 0.11 (0.24 ± 0.09)
Treated	5.12 ± 0.35 (2.53 ± 0.11) <sup>a</sup>	1.32 ± 0.16 (0.65 ± 0.05)	0.61 ± 0.05 (0.30 ± 0.01)	1.99 ± 0.39 (0.99 ± 0.24)	0.58 ± 0.15 (0.29 ± .07)

Data are expressed as mean ± SEM, n=6. Superscripted letter indicates significant difference between mean

**Table 3: Effect of oral administration of *B. vogeliana* leaves extract on biochemical parameters**

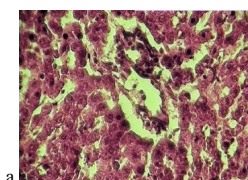
Parameters	Groups	
	Control	Treated
Urea nitrogen (mg/dl)	0.375 ± 0.007	0.330 ± 0.036
Creatinine (mg/dl)	5.70 ± 0.28	5.73 ± 0.40
Alkaline phosphatase (U/I)	22.50 ± 6.65	18.10 ± 3.21
ASAT (U/I)	270.50 ± 17.68	264. ± 41.04
ALAT (U/I)	179.50 ± 10.61	163.33 ± 30.14
Calcium (mg/dl)	9.20 ± 0.71	10.27 ± 0.31
Alpha amylase (U/I)	11.75 ± 2.05	24.03 ± 3.11 <sup>a</sup>
Total protein (g/dl)	61.20 ± 1.27	66.60 ± 1.65 <sup>a</sup>
Phosphorus (mg/dl)	86.50 ± 10.61	100.33 ± 1.53

Data are expressed as mean ± SEM, n=6. Superscripted letter indicates significant difference between means.

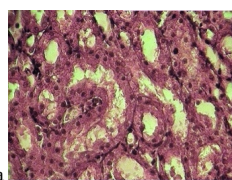
**Table 4: Hematological parameters after 14 days of treatment with the *B. vogeliana* aqueous extract**

Parameters Groups	WBC (×10 <sup>6</sup> /ml)	Lymphocyte	RBC (M/μl)	HGB (g/dl)	Haematocrit (%)	PLT (×10 <sup>6</sup> /ml)
Control	12.50±1.27	9.70±0.49	8.86±0.23	13.60±0.99	44.95±0.78	175 ± 48.0
Treated	11.56±4.06	9.46±3.19	7.35±0.98	12.98±1.28	39.50±4.77	198 ± 49

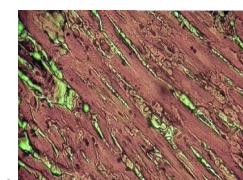
Data are expressed as mean ± SEM, n=6.



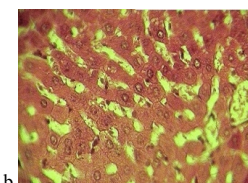
a



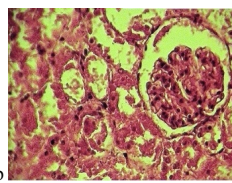
a



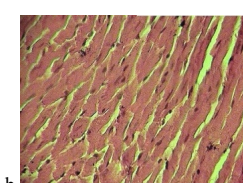
a



b



b

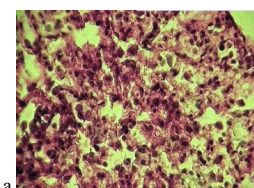


b

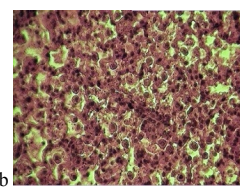
**Figure 1: Photomicrographs of liver section of rat stained with heamatoxylin and eosin (×400); a: control or normal rat; b: rat treated 2000mg/kg.**

**Figure 2: Photomicrographs of kidney section of rat stained with heamatoxylin and eosin (×400); a: control or normal rat; b: rat treated 2000mg/kg.**

**Figure 3: Photomicrographs of heart section of rat stained with heamatoxylin and eosin (×400); a: control or normal rat; b: rat treated 2000mg/kg.**



a



b

**Figure 4: Photomicrographs of lung section of rat stained with heamatoxylin and eosin (×400); a: control or normal rat; b: rat treated 2000mg/kg.**



Figure 5: Photomicrographs of spleen section of rat stained with hematoxylin and eosin ( $\times 400$ ); a: control or normal rat; b: rat treated 2000mg/kg.

## DISCUSSION

The aim of this study was to study the acute toxicity of the aqueous extract of *Brillantaisia vogeliana* leaves. The increase in the body weight of rats was found in both of the tested and control groups (Table 1). This could be due to the stimulation of food intake which was clearly measured in this study or an effect on energy expenditure by body tissues<sup>6</sup>.

No significant difference was observed in relative organ weight, except the relative liver weight which was lower in treated group than control group. However, a reduction has been detected in the liver weight, showing a particular effect on liver cells.

The measurement of enzyme activities in tissues and body fluid plays a significant and well defined role in investigation and diagnosis of diseases<sup>7</sup>. Such measurement can also give an insight to the site of cellular tissues damage as a result of assault by acute, sub-acute or chronic use of plant extract. Tissues enzyme assay can indicate cellular damage long before structure damage which could be proved by conventional histological techniques. Their estimation in the serum is a useful quantitative marker of the extent and type of hepatocellular damage<sup>8</sup>. The estimation of the activities of ALAT, ASAT and ALP can make assessment of liver function. Alkaline phosphatase is a marker for the plasma membrane and endoplasmic reticulum functionality<sup>9</sup>. In fact, alkaline phosphatase activity is often employed to assess integrity of plasma membrane and endoplasmic reticulum<sup>10</sup>. For example, when liver cell plasma membrane is damaged by hepatotoxic substances, a variety of enzymes normally located in the cytosol are released into the blood stream through injured liver cell wall<sup>11</sup>.

The specific site of oxidative damage of some of the susceptible amino acids of proteins is now regarded as the major cause of metabolic dysfunction during pathogenesis<sup>12</sup>. Hence, a decline of the total protein content can be deemed as a useful index of the severity of the cellular dysfunction in chronic liver diseases. Then, the increased level of total proteins recorded in serum (Table 3) of treated rats might reveal hepatoprotective effect of the extract, despite the significant decrease in relative weight of liver which could be an artifact because the rate of ASAT and ALAT did not reveal any significant difference between both control and treated groups. Blood analysis exhibited significant increased of total protein, ruling suggestive harmful effect on glomerular permeability. In addition, renal markers of functionality like urea and creatinine levels did not show an expressive alteration.

In regard to phosphorus, phosphate groups are needed to synthesize two major membrane components such

phospholipidylethanolamine and phosphatidylcholine which are important in the membrane fluidity and the permeability of the epithelial cells<sup>13</sup>. The changes in plasma amylase are usually associated with pancreatic disease in most living species. It may also explain an indication of a hepatic effect, since all isoenzyme forms of amylase are also present in rat hepatocytes<sup>14</sup>. In addition, since organ-specific amylase isoenzyme was not quantified in this study, it is uncertainly at this time to know whether dose-related changes in amylase reflect a liver and/or pancreatic effect<sup>15</sup>.

In conclusion, the oral administration 2 g/kg of aqueous extract of *Brillantaisia vogeliana* did not have any hematological effect or slight effect in biochemical parameters. LD<sub>50</sub> was greater than 2000 mg/kg, and then according to whitehead and stallard<sup>16</sup>, it is not a toxic substance or a class 5 substance.

## ACKNOWLEDGMENT

We thank Dr SOLLE Geremie and Dr MBANGUE Madeleine, chief of service of Laquintinie Hospital laboratory, for providing necessary facilities. We acknowledge Pr. FEWOU Amadou, Head of Anatomopathology laboratory service of Douala Laquintinie Hospital for facilities support during histopathology studies.

## REFERENCES

1. Wabo PJ, Mpoame M and Bilong BCF. Acute and sub-acute toxicity of ethanolic extract of *Canthium mannii* Hiern stem bark on *Mus musculus*. *Ind. Journ. Exp. Biol.*, 2011; 49: 146-150.
2. Fouché GJ, Hambuckers A, Marquet A and Angenot L. Plantes médicinales: de la plante au médicament. Observatoire du monde desplantes. (Sart-tilman-liège), 2001. <http://biodiversity.uno.edu/delta/march 2007.19.055>
3. Wickramasingh BM. Quality control screening, toxicity and regulation of herbal drug. *in modern phytomedicine*. Turning medicinal plants into drugs edited by Iqbal Ahmed, Farrukh Ail and Mohammad Owais (wiley-vch verlag gmbh and Co GoA, weinheim), 2006, p. 25
4. Noubissi KF. Etude des effets de *Brillantaisia vogeliana* (Nées) Benth. (Acanthacées) sur le taux des lipides sériques chez les rats. Thèse de Doctorat 3<sup>ème</sup> cycle Université de Yaoundé I, 2000
5. Stallard N and whitehead A. A statistical evaluation of the fixed dose procedure. *Atla*, 2004; 32 suppl 2:13-21.
6. DA Costa LL, Albano F, Laranja GAT, Alves LM, Silva LFM, DE Souza GP, Araujo IM, Neto JFN, Felzenszwalb I, Kovary K. Toxicological evaluation by in vitro and in vivo assay of an aqueous extract prepared from *Echinodorus macrophyllus* leaves. *Toxicol. Letters*, 2000; 116: 189-198. [http://dx.doi.org/10.1016/S0378-4274\(00\)00220-4](http://dx.doi.org/10.1016/S0378-4274(00)00220-4)
7. Malomo SO. Toxicological implication of Ceftriaxone administration in rats. *Nigeria J. Bioch. Mol. Biol.* 2000; 15: 33-38.
8. Miltra SK, Venkataranganna MV, Sundaram R, Gopumadhavan S. Protective effect of HD-03, a herbal formulation, against various hepatotoxic agents in rats. *J. ethnopharmacol.*, 1998; 63: 181-186. [http://dx.doi.org/10.1016/S0378-8741\(98\)00088-9](http://dx.doi.org/10.1016/S0378-8741(98)00088-9)
9. Wright PJ and Plummer DT. The use of urinary enzyme measurement of direct renal damaged caused by nephrotoxic compound. *Biochem. Pharmacol.*, 1974; 23: 65-73. [http://dx.doi.org/10.1016/0006-2952\(74\)90314-1](http://dx.doi.org/10.1016/0006-2952(74)90314-1)
10. Akanji MA, Olangoke OA and Oloyede OB. Effect of chronic consumption of metabisulfite on the integrity of the kidney cellular

- system. *Toxicol.*, 1993; 81: 173-179. [http://dx.doi.org/10.1016/0300-483X\(93\)90010-P](http://dx.doi.org/10.1016/0300-483X(93)90010-P)
11. Lim HK, Kim HS, Chung MW and Kim YC. Protective effects of bergenin, the major constituent of *Mallotus japonicum*, on galactosamine-intoxicated rat hepatocytes. *Journ. of ethnopharma.*, 2000; 70: 69-72
  12. Uday B, Das D, Banerjee KR. Reactive oxygen species: oxidative damage and pathogenesis. *Curr. Sci.*, 1999; 77 : 658-668
  13. Malbika JO and Hart LG. Effect of Adenosine triphosphate (ATP) and anti-inflammatory agents on purified lysosomal having high acid phosphatase and labile glucuronidase activity. *Bioch. pharm.*, 1971; 20: 2017-2022.
  14. Loeb WF. The rat. *Clin. Chem. of lab*, 1999; 33-48
  15. Rogers VV, Wickstrom M, Liber K and Mackinnont DM. Acute and subchronic Mammalian toxicity of naphthenic acids from oil sands tailings. *Toxicol Sci.* 2002; 66: 347-355 <http://dx.doi.org/10.1093/toxsci/66.2.347> PMID:11896302
  16. Whitehead A and Stallard N. Opportunities for reduction in acute toxicity testing via improved design. *Atla*, 2004; 32 suppl 2:73-80.

**Cite this article as:**

Aimé Valère SOH OUMBE, Constant Anatole PIEME, Amadou FEWOU, Mathieu NDOMOU, Jeanne NGOGANG YONKEU. Acute toxicity of the aqueous extract from *Brillantaisia vogeliana* (Nées) Benth. (Acanthaceae). *Int. J. Res. Ayurveda Pharm.* 2013; 4(2):158-162

Source of support: Nil, Conflict of interest: None Declared